

*Full Length Research Paper*

# **Trematocidal activity of certain plant species against rumen fluke *Fischoederius cobboldi***

**Praveen Krishnakumar<sup>1,2</sup>, Madhuri Menon<sup>1,2</sup>, Asha Rajagopal<sup>2</sup> and Leyon Varghese<sup>1\*</sup>**

<sup>1</sup>Immunology and Toxicology Research Laboratory, Department of Zoology, Christ College (Autonomous), University of Calicut, Irinjalakuda, 680125, India.

<sup>2</sup>Department of Veterinary Parasitology, College of Veterinary and Animal Sciences, Kerala Veterinary and Animal Sciences University, Mannuthy, Thrissur, 680651, India.

Received 28 November, 2020; Accepted 19 April, 2021

The anthelmintic potential of twelve solvent extracts of four plant species were studied against adult *Fischoederius cobboldi* using *in vitro* systems. Generally, the ethyl acetate extracts of all the plants showed prominent activity by inhibiting the fluke's motility and reducing their survival in a concentration dependent manner. Compared to the vehicle control a very significant ( $P < 0.0001$ ) mortality rate was observed for the *Kaempferia rotunda* ethyl acetate extract (25 mg/ml) treated flukes within 1 h of treatment. The alcohol extracts were also effective in inducing mortality with a prolonged treatment of 2 h, whereas the water extracts of all the four plants were least effective in killing these worms. Microscopy studies of these flukes revealed considerable morphological alterations to the surface syncytium, teguments, and suckers. Treatment of ethyl acetate and alcohol extract induced irregular lesions and severe degradation to the teguments. Alterations to the surface morphology were less with water extract treatment. The histological examinations revealed the loss of collagen in the cuticle as well as in the interior tissues of the trematode in these organic solvent extract treated animals. The qualitative screening of the extracts revealed the presence of flavonoids phenols and tannins with varying levels. Synergistic multi-targeted actions of these molecules are expected to contribute to the observed trematocidal activity of these plant extracts. The extract is therefore proposed for veterinary use after toxicity studies.

**Key words:** *Lagenandra toxicaria*, *Kaempferia rotunda*, *Desmodium gangeticum*, *Tragia involucrata*, extracts, *Fischoederius cobboldi*, paramphistomosis, trematocidal.

## **INTRODUCTION**

*Fischoederius cobboldi* is a digenetic trematode parasite of the family Gastrothylacidae. They are considered as one of the important agents causing paramphistomosis in livestock, mainly cattle and sheep throughout the world. Ruminants like cattle, goat, sheep and water buffaloes

are infected by rumen flukes. The life cycle involves a definitive host (DH) and an intermediate host (IH). Mammals are the definitive host, and the infection occurs when DH ingest metacercaria passively. The flukes remain in the small intestine for a while and move to the

\*Corresponding author. E-mail : [leyon@christcollegeijk.edu.in](mailto:leyon@christcollegeijk.edu.in)

rumen when it reaches the adult stage (Sanguankiat et al., 2016). The disease adversely affects nutrition conversion and milk production. This also induces weight loss that ultimately leads to decreased productivity, resulting in huge economic losses in many countries (Tehrani et al., 2015, Choubisa and Jaroli, 2013, Murthy and Rao, 2014, Dorny et al., 2011). The economic loss due to paramphistomosis is very high with morbidity and mortality rates of about 80 to 90% to domesticated animals and is prevalent for decades together (Anuracpreeda et al., 2015; Hanna et al., 1988; Kaur et al., 2008; Tariq et al., 2008). Paramphistomosis is generally treated with the help of synthetic anthelmintic drugs, but the resistance and resurgence of flukes against synthetic compounds have been a serious cause of concern in paramphistomosis treatment. Many herbal extracts are considered as safe alternatives with decreased non-targeted effects and economic viability against paramphistomosis management (Swarnakar and Kumawat, 2014).

The use of medicinal plants to treat parasitic infections in livestock dates back to several centuries and ethnoveterinary medicine draws inspiration from such traditional practices. Gastro intestinal parasitism has been treated with the help of seeds from garlic, onion and mint (Athanasiadou et al., 2007). *Desmodium gangeticum* belongs to family Fabaceae, spread across India, China, Africa and Australia is an important plant used in the indigenous medicine and is proven to be effective in the treatment of typhoid, inflammation, piles, asthma, bronchitis, dysentery and various neurological disorders in humans (Kirtikar and Basu, 1987). *Tragia involucrata* (family Euphorbaceae) is also a less explored traditional medicinal plant, widely dispersed throughout India, reported to possess anticonvulsive components and is recommended as effective in treating partial seizures (Varma et al., 2014). It is also reported to have strong anti-diabetic effects and is one of the main ingredients in the anti-diabetic formulations available in the market (Kar et al., 2003). *Kaempferia rotunda* L. used in the present study is an aromatic herb that comes under the family Zingiberaceae. It is indigenous to south-east Asia and cultivated for different medicinal purposes (Woerdenbag et al., 2004). Plant parts, mainly rhizome, are traditionally used for treating abdominal pain, dysentery, cold, obesity, and diarrhea in humans (Heinrich, 2003). Previous studies have also exposed the antibacterial, antiproliferative, anti-mutagenic, and antioxidant activities (Atun et al., 2013; Kabir et al., 2011; Priya Mohanty et al., 2008) of *K. rotunda*. Another plant *Lagenandra toxicaria* (family Araceae) that have not been mentioned in the Ayurvedic literature such as Ayurvedic Pharmacopeia, and is reported to be an adulterant for *K. rotunda* in many places (Sereena et al., 2011). On the contrary there are also certain reports showing the plant has several bioactive properties such as antibacterial activity (Selvakumari, 2014). The present study is designed to

evaluate the anthelmintic potentials of ethyl acetate, ethanol, and water extracts of these four plants against animal parasitic trematode *F. cobboldi*. The phytochemical analysis of the extracts was also done to highlight the role of secondary metabolites in providing the medicinal properties of the plants.

## METHODOLOGY

### Plant collection, authentication and extraction

Healthy plants were collected during the months of November and December 2019 from their natural habitat in different parts of Kerala, India. Plant materials were subjected to morphological identification at the Department of Botany, University of Calicut, Kerala, India, and herbarium specimens are kept there (*L. toxicaria* 7001 and *K. rotunda* 7002) for future reference. Voucher specimens of *D. gangeticum* and *T. involucrata* were submitted at Kerala Forest Research (KFRI), Thrissur Kerala, for authentic identification and deposited there with accession numbers 17683 and 17682, respectively. The rhizome part of *K. rotunda* and *L. toxicaria* as well as the whole plant components of *D. gangeticum* and *T. involucrata* were shade dried, powdered, weighed (15 g) and extracted separately in 200 ml of ethyl acetate, ethanol, and water for 10 min using accelerated solvent extractor (Dionex ASE 150, Thermoscientific). Thereafter, each extract was evaporated to dryness using a rotary evaporator and the resulting crude extracts were stored under refrigeration until further use.

### Phytochemical screening

Qualitative phytochemical screening of the extracts was executed to identify the important secondary metabolites. The concentrated extracts were used for the screening of alkaloids, phenols (Darnley, 1974), saponins (Adesegun et al., 2008), tannins (Evans et al., 2002) and flavonoids (Paech, 1962).

### Collection of flukes for bioassays

Adult *F. cobboldi* were freshly collected from the rumens of infected cattle killed for consumption in a local slaughterhouse and were transferred to laboratory in pre-warmed tyrode's solution. They were then washed in phosphate buffer saline (PBS pH 7.2) (Aggarwal et al., 2016). The adulticidal assay of the plant extracts were conducted on *F. cobboldi* according to the method proposed by Anuracpreeda et al. (2015). Briefly, adult flukes were randomly selected and 25 flukes for each test concentration, positive and vehicle controls were used for the study. Group 1 served as the vehicle control (0.1% DMSO alone); group 2 with 1 mg/mL of Albendazole (ABZ) served as positive control; groups 3 to 5 were treated respectively with ethyl acetate, ethanol and water extracts at various concentrations (25, 12.5, 6.25 and 3.125 mg/mL). Three replicates were kept for each group. The treatment continued for 2 h and was observed under a stereomicroscope (Leica M205 C) for motility at different time points. The time required for total inactivity or paralysis followed by the death of fluke was recorded, and the tegumental changes were examined under microscope. The motilities of the flukes were scored at each incubation period according to the method proposed by Kiuchi et al. (1987). The death of the flukes was confirmed by disturbing them using a needle.

**Table 1.** The yield of extraction for the four plants.

Name of the plant	Plant part	Solvent	Code	Yield (%)
<i>Lagenandra toxicaria</i>	Rhizome	Ethyl acetate	LTE	3
		Ethanol	LTOH	8
		Aqueous	LTW	15
<i>Kaempferia rotunda</i>	Rhizome	Ethyl acetate	KRE	4.5
		Ethanol	KROH	9.7
		Aqueous	KRW	14.6
<i>Desmodium gangeticum</i>	Whole plant	Ethyl acetate	DEE	2.0
		Ethanol	DME	10.5
		Aqueous	DWE	5.0
<i>Tragia involucrata</i>	Whole Plant	Ethyl acetate	TEE	2.0
		Ethanol	TME	10.4
		Aqueous	TWE	5.0

### Histology analysis

The fluke specimens were prepared for histology examination by the method proposed by Anuracpreeda et al. (2013, 2014). Dead *F. cobboldi* from each group were fixed in Bouin's fixative solution for 12 h, and then was transferred to 10% formalin for further histological processing. Sections of the tissues were taken and stained using hematoxylin and eosin and observed for abnormalities and photographed under a light microscope (Leica TCM 400). The amphistomes fixed in 10% formalin were also sectioned and subjected to Masson's trichrome staining to observe changes in the connective tissues.

### Statistical analysis

The efficacies of the tested extracts against adult *F. cobboldi* were based on calculated Relative Motility (RM) values using the formula:

$$\text{RM Value} = (\text{MI test} \times 100) / \text{MI Control}$$
$$\text{Motility Index (MI)} = (\sum nN)/N$$

where n=motility score and N=number of flukes with the score of n.

The survival data was analysed using Graph Pad Prism software version 5. The Log-rank (Mantel-Cox) test was executed for comparing the survival curves.

## RESULTS

### Extraction and phytochemical screening

Three solvents were selected for extraction with different relative polarity levels: ethyl acetate being the least polar, ethanol on a higher scale, and water being the most polar. Ethyl acetate was given the lowest yield for all the four plant sample's extraction. For the rhizome sample of *L. toxicaria* and *K. rotunda*, aqueous extraction was given the highest yield whereas when we use the whole plant

part of *D. gangeticum* and *T. involucrata*, ethanol extraction was given the highest yield (Table 1). Qualitative phytochemical analysis showed the presence of different categories of secondary metabolites in all the extracts. Among these bioactive molecules identified, phenolic classes of secondary metabolites were abundantly present in the extracts. Flavonoids were present in all the twelve extracts tested. Alongside almost all extracts showed the presence of polyphenols and tannins. Alkaloids were totally absent in the extracts of *K. rotunda*, so also the ethyl acetate extracts of all other three plants. *L. toxicaria*, *D. gangeticum* and *T. involucrata* showed the presence of alkaloids in their ethanol extract. Presence of alkaloids was also identified in water extract of *L. toxicaria* and *D. gangeticum* (Table 2).

### Bioassay using *F. cobboldi*

The *in vitro* study of the extracts against *F. cobboldi* showed a decreased relative motility (RM) values decreased with an increase in concentration and treatment duration. All flukes treated with vehicle control remained active throughout the experimental period with high RM value. The broad-spectrum synthetic drug, ABZ here served as positive control gave consistent results with previous observations (Anuracpreeda et al., 2016; Halton, 2004; Hossain et al., 2012). The ABZ (1 mg/ml) treated flukes started showing decreased survival after 1 h of treatment and almost 75 to 85% of the flukes died in this group in 2 h of time. The nonmotile flukes were confirmed dead or paralysed by pricking it with a needle and watching for its response. Among the twelve extracts, KRE (25 mg/ml) was the most active as it

**Table 2.** Qualitative phytochemical analysis of the extracts

Extract		Plant species											
		<i>L. toxicaria</i>			<i>K. rotunda</i>			<i>D. gangeticum</i>			<i>T. involucreta</i>		
		LT E	LTOH	LT W	KR E	KROH	KRW	DE E	DME	DW E	TE E	TME	TWE
Type of phytochemical	Alkaloids	-	+	+	-	-	-	-	+	+	-	+	-
	Flavonoids	+	+	+	+	+	+	+	+	+	+	+	+
	Polyphenols	+	+	+	+	+	+	+	+	+	-	+	+
	Tannins	+	+	-	+	+	+	+	+	+	+	+	+
	Saponins	-	-	-	-	-	-	-	-	-	-	-	+

+: Presence, -: absence.

caused 100% mortality in the first hour of treatment itself. The Log-rank (Mantel-Cox) test compared the significance of survival curves in which all the ethyl acetate extract treated groups of animals showed significant ( $P < 0.0001$ ) mortality as compared to the vehicle treated animals (Figure 1A, 2A, 3A and 4A). Prolonged treatment of 2.0 h resulted in increased amphistome mortality in the higher concentrations of all the ethanolic extract treated animals. Aqueous extracts of all the four plants on the other hand did not show any significant adulticidal activity at these concentrations (Figures 1 to 4).

### Morphological examinations

Stereomicroscopic observations of the dead animals showed prominent morphological alterations whereas 2 h post-treatment in vehicle control animals had intact oral structures and acetabulum. No alterations were observed on the ventral or dorsal surface of these flukes. Whereas 1.5 h post-treatment in 1 mg/ml of ABZ induced changes to the acetabulum and mild tegumental erosion could also be observed (Figure 5). However, the tegumental degeneration and tegumental erosion associated with tegumental sloughing increased after 2 h of treatment. Degradation of outer surface; color and size change throughout the whole body; swellings and other alterations to the surface architecture could also be observed. Serious tegumental sloughing and degeneration were also observed with extract treated animals. Extensive erosion of membrane surface which leads to irregular lesions was also observed at the ventral surface of the ethyl acetate extract treated samples (Figure 5).

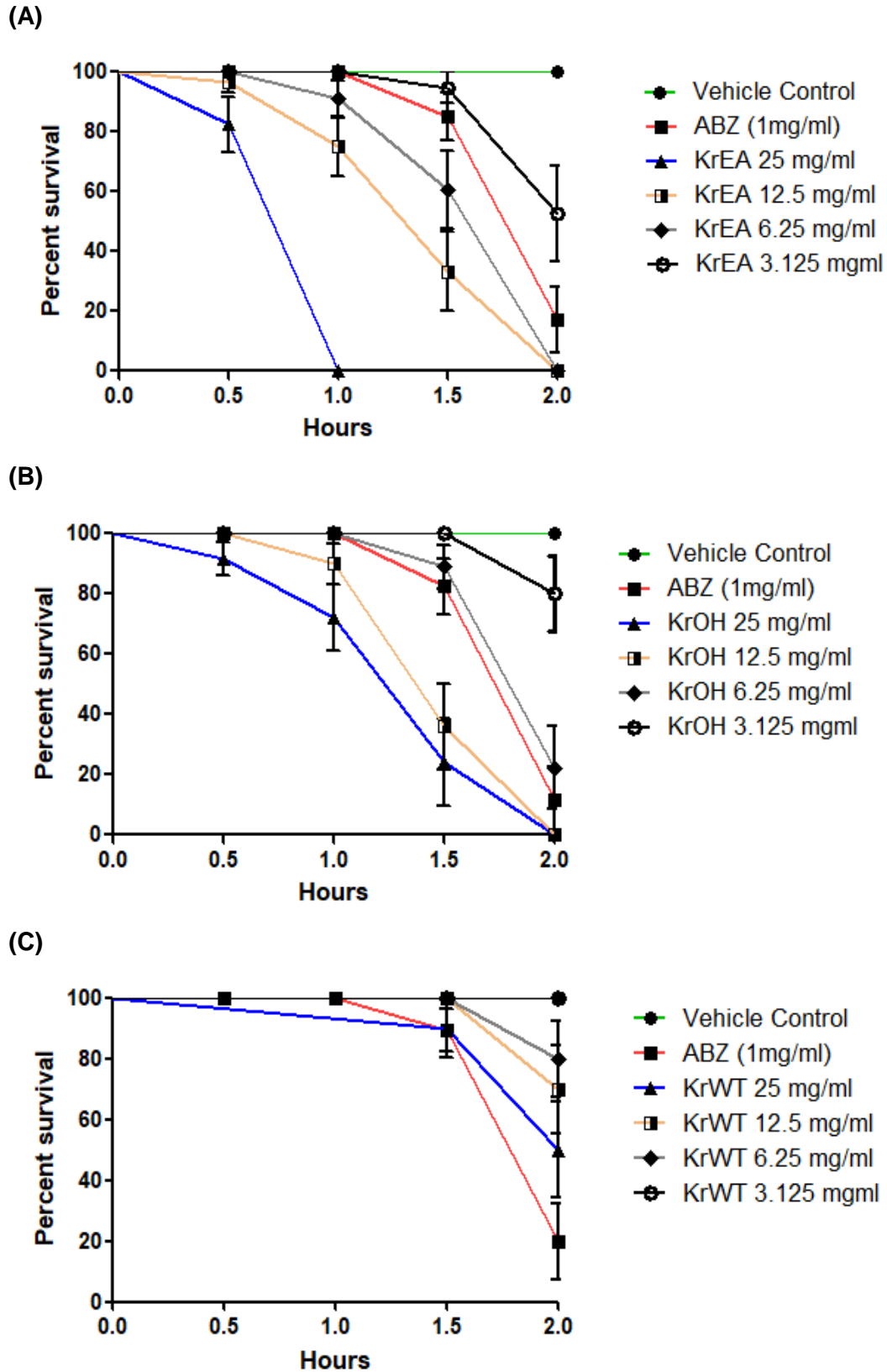
### Histological study

The H&E staining of the sections revealed a corrugated appearance to the outer body cuticle in the vehicle control *F. cobboldi* incubated for 1.5 h in 1 mg/ml of ABZ

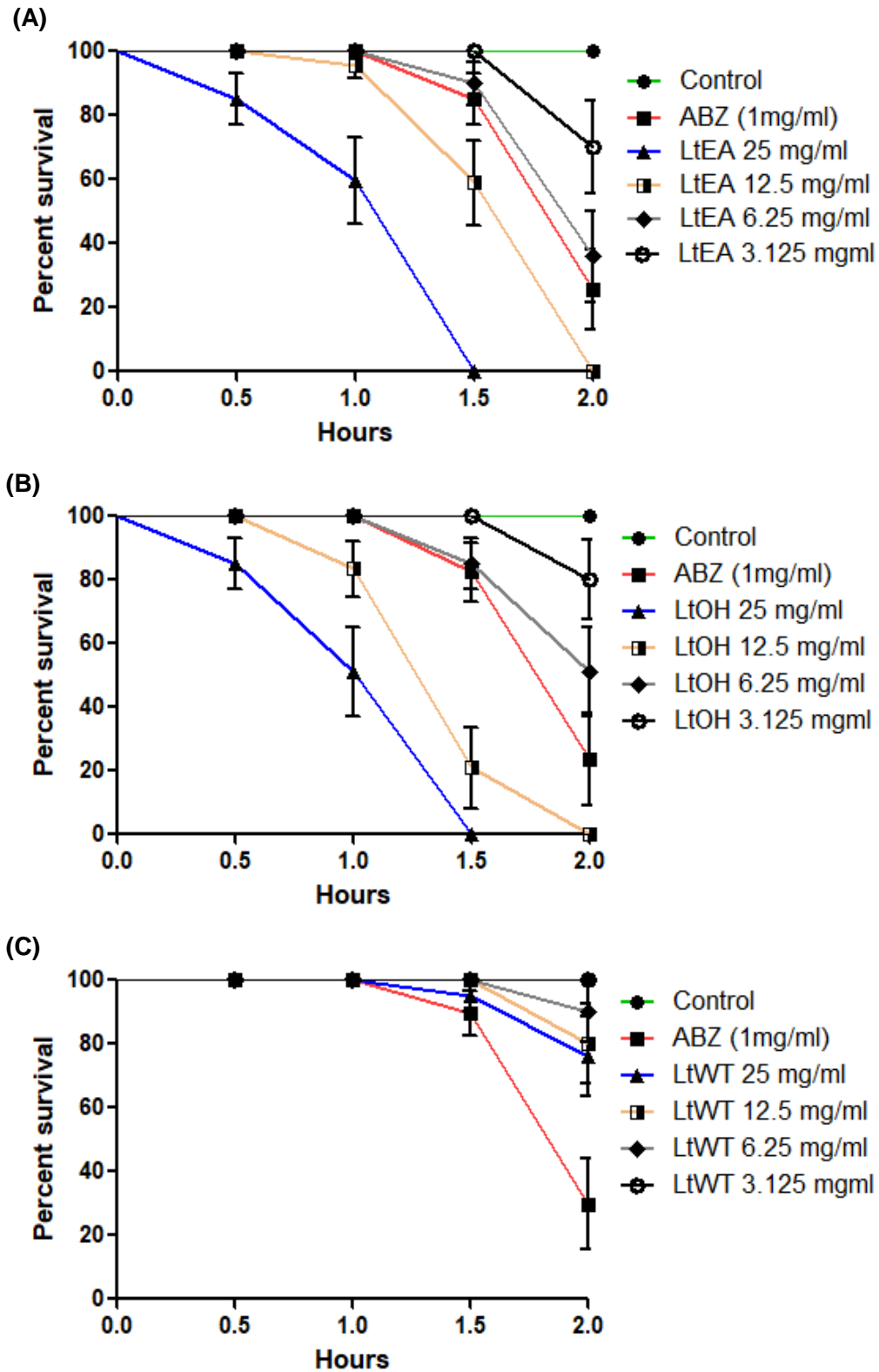
exhibited mild degeneration to surface syncytium but the underlying muscle appears normal. Following 2 h treatment, there was severe degeneration to the surface syncytium and teguments followed by detachment from the basement membrane was observed (Figure 6) in these animals. The extract treated flukes exhibited severe concentration dependent changes to the surface syncytium, tegumental folds, grooves and the underlying muscle structures. Increase in concentration and duration critically increased the degeneration of teguments and associated structures. The Masson's trichrome staining revealed changes in the connective tissue structures of the animals treated with the extracts (Figure 7). The intense blue colour on the body wall indicates the presence of collagen in the vehicle control animals whereas the absence of blue colour and smooth cuticle (with decreased corrugations) showed the absence of collagen and degradation of the cuticular layer in them. The absence of collagen was also observed in the inner regions of the worm other than the cuticle as shown in Figure 6.

### DISCUSSION

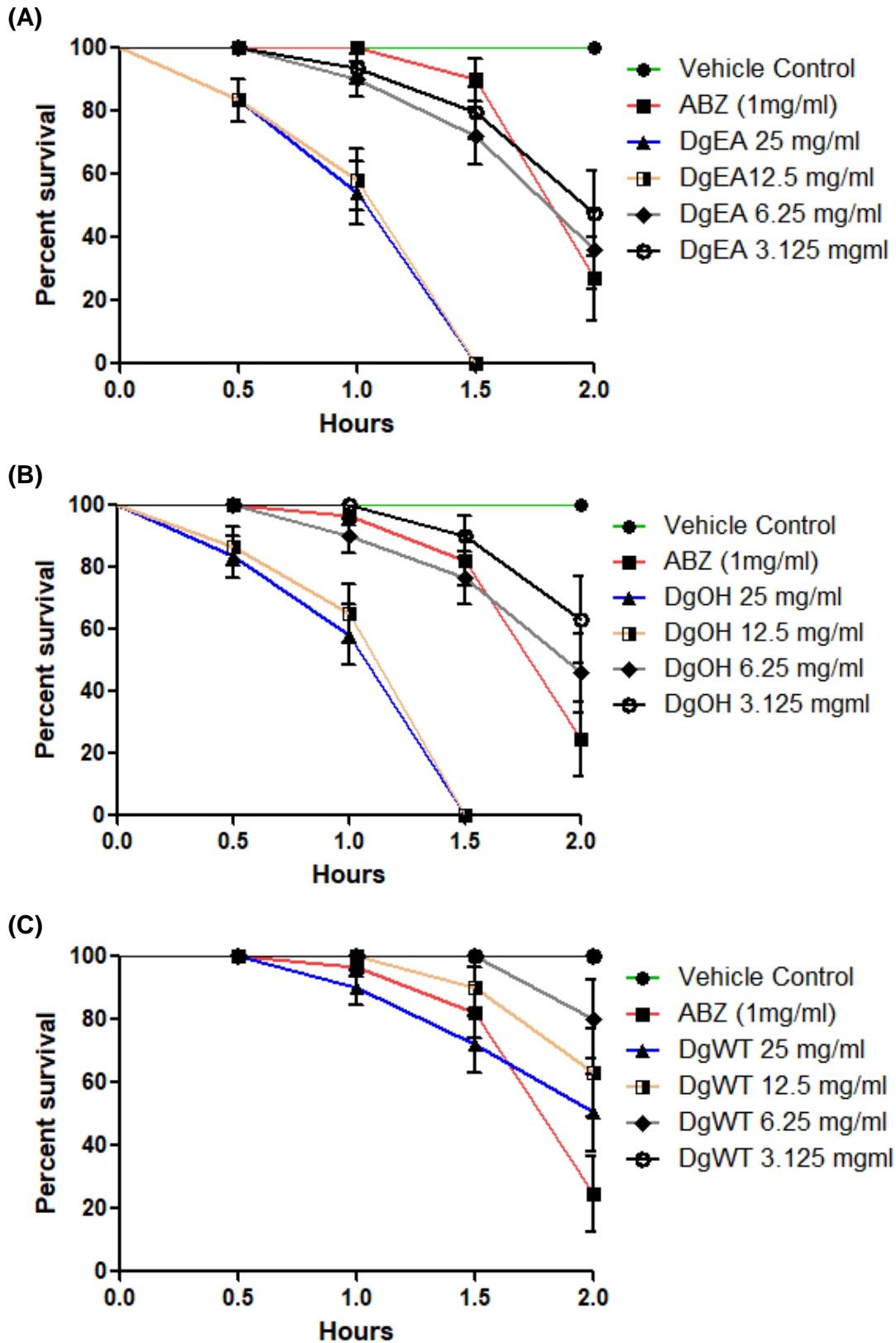
Amphistomes including *Fischoederius* genus, commonly referred to as 'stomach' or 'rumen' flukes because of the localization of these flukes in the stomach of ruminants, are digenetic trematodes distinguished by the absence of an oral sucker and the position of the ventral sucker or acetabulum at the posterior end of the body (Tandon et al., 2014). The tegumental surface exhibits high corrugation and transverse folds alternating with grooves and are without spines. The ventral surface has more complex corrugations and invaginations than those of the dorsal surface of the body (Anuracpreeda et al., 2012). The tegumental region of the parasite is important in that they help evade many of the host defenses effectively. It plays a chief role in protecting the flukes from host enzymes and immune responses. Additionally, it supports the internal organs, helps maintain the absorption and exchange of nutritive and waste products, maintains osmoregulation and perceives sensory stimuli



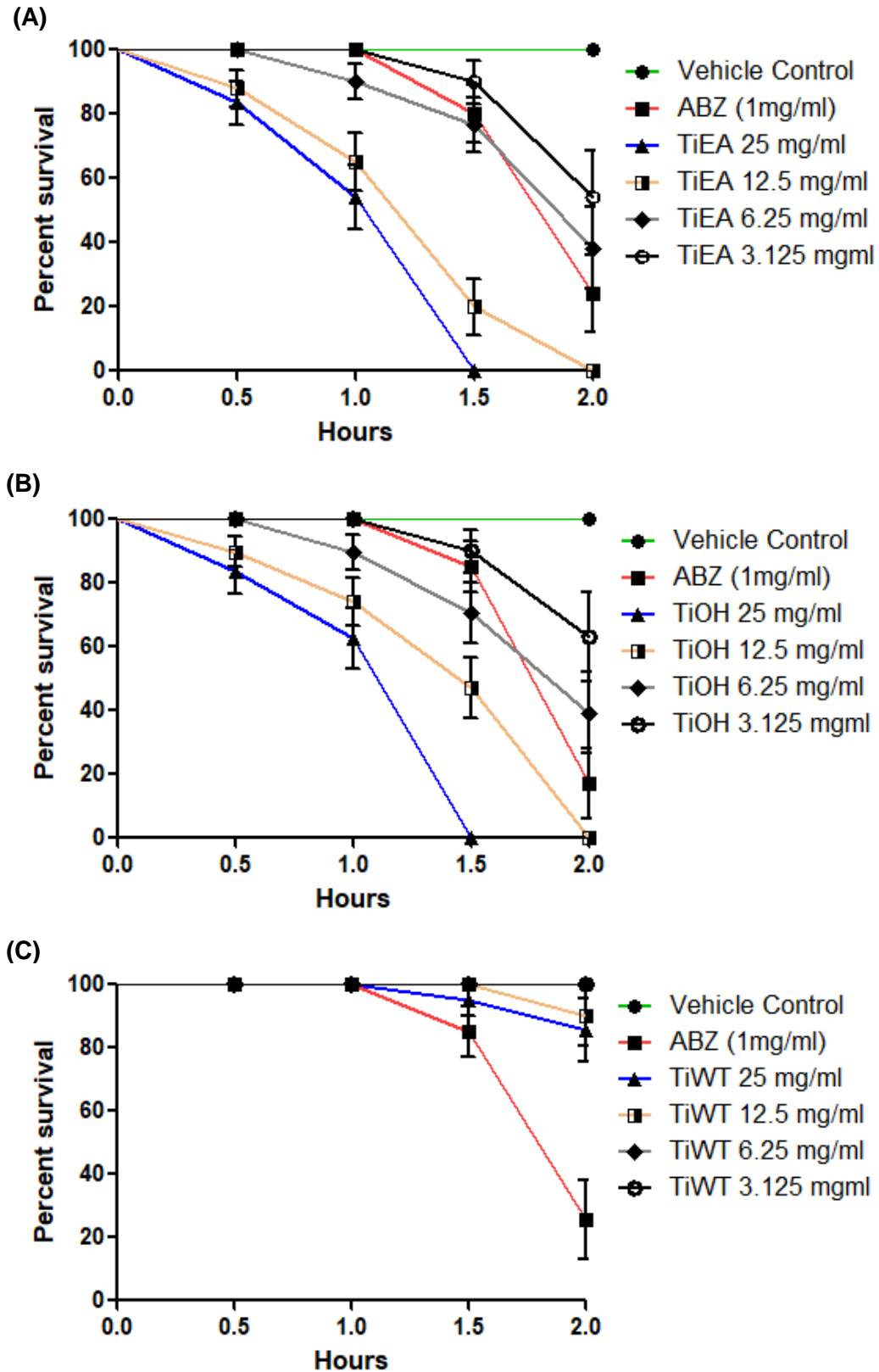
**Figure 1.** The survival study of adult *F. cobboldi* treated with *Kaempferia rotunda* extracts. (A) KRE (KrEA), (B) KROH (KrOH) and (C) KRW (KrWT) at various concentrations and time intervals are illustrated. The significance of survival curves by Log-rank (Mantel-Cox) Test showed  $P < 0.0001^*$  when the highest concentration (25mg/ml) treatment was compared to the vehicle control.



**Figure 2.** The survival study of adult *F. cobboldi* treated with *Lagenandra toxicaria* extracts. (A) LTE (*L.toxi* EA), (B) LTOH (*L.toxi* OH) and (C) LTW (*L.toxi*WT) at various concentrations and time intervals are illustrated. The significance of survival curves by Log-rank (Mantel-Cox) Test showed  $P < 0.0001$  \* when the highest concentration (25mg/ml) treatment was compared to the vehicle control.

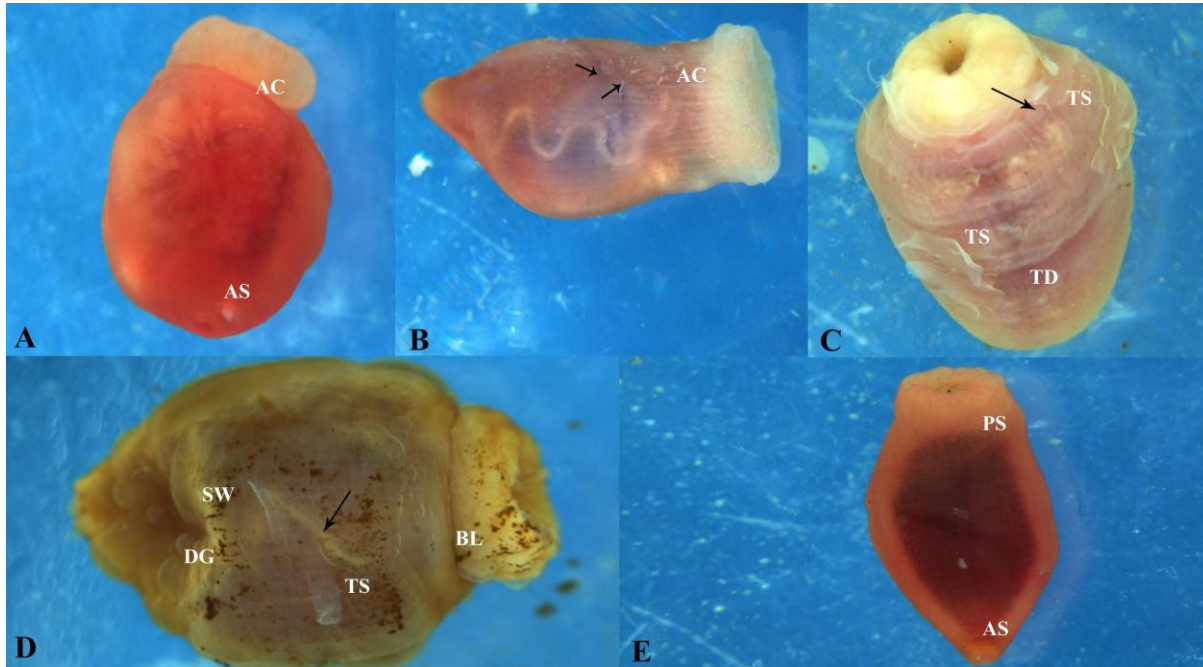


**Figure 3.** The survival study of adult *F. cobboldi* treated with *Desmodium gangeticum* extracts. (A) DEE (DgEA), (B) DME (DgOH) and (C) DWE (DgWT) at various concentrations and time intervals are illustrated. The significance of survival curves by Log-rank (Mantel-Cox) Test showed  $P < 0.0001^*$  when the highest concentration (25mg/ml) treatment was compared to the vehicle control.



**Figure 4.** The survival study of adult *F. cobboldi* treated with *Tragia involucrata* extracts. (A) TEE (TiEA), (B) TME (TiOH) and (C) TWE (TiWT) at various concentrations and time intervals are illustrated. The significance of survival curves by Log-rank (Mantel-Cox) Test showed  $P < 0.0001^*$  when the highest concentration (25mg/ml) treatment was compared to the vehicle control.





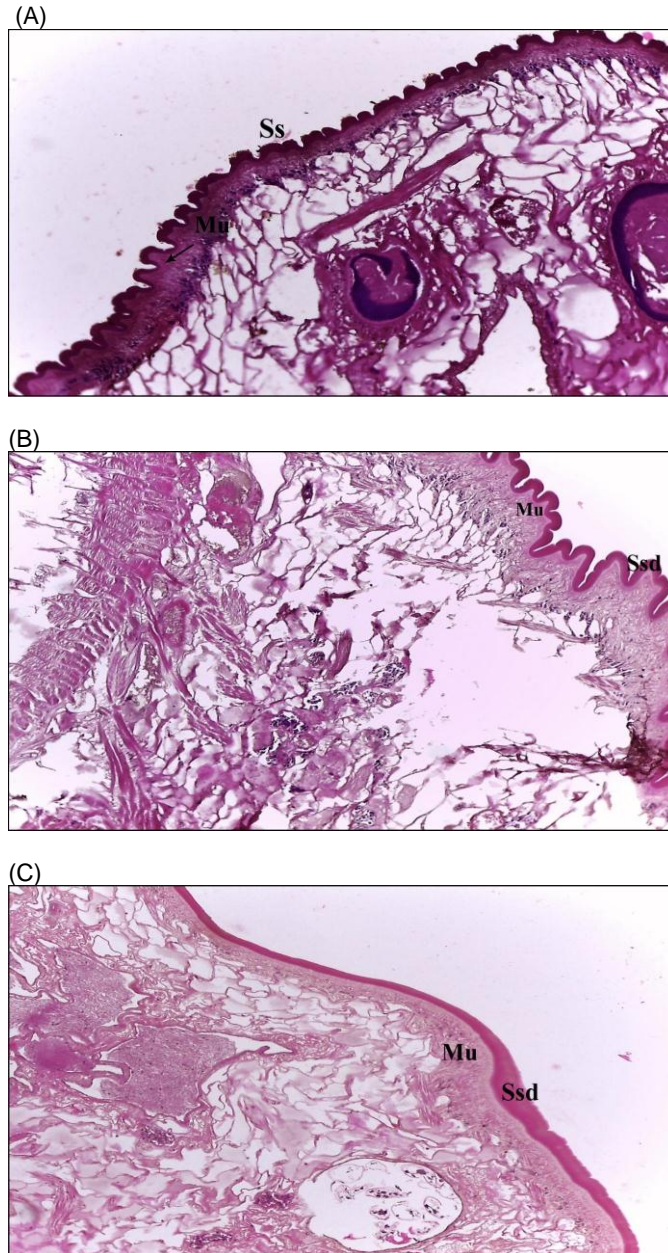
**Figure 5.** Morphology of the adult *F. cobboldi* treated with vehicle control, ABZ and plant extract. (a) Two hours post-treatment in vehicle control showing intact anterior oral structure (AS) and acetabulum (AC). (b) Treatment in ABZ (1 mg/ml) for 2.0 hours showing changes to the acetabulum (AC) and tegumental erosion (→). (c): KRE treatment showing severe tegumental sloughing (TS) throughout the body surface. Extensive erosion which leads to irregular lesions were also observed at the ventral surface. (d): KROH treatment showing irregular swollen tegumental regions (SW) with deep grooves (DG) and blebs (BL) around posterior sucker regions. Severe tegumental degeneration (TD) associated with tegumental sloughing (TS). (e): Water extract treated samples show intact posterior sucker and anterior oral structures (PS & AS) with negligible tegumental degeneration.

(Apinhasmit et al., 1994; Meaney et al., 2002, 2003, 2004; Sobhon and Upatham, 1990). The present study showed important alterations to the tegumental regions including severe degeneration and sloughing followed by extensive erosion when treated with the extracts.

The rapid spread of resistance to synthetic anthelmintic drugs such as Oxytoclozanide and Triclabendazole, paved cause huge mortality to adult flukes in a short span of time. The RM value was reduced to zero within 1 h of incubation at 25 mg/ml of KRE treatment. Earlier Anuracpreeda et al. (2016) reported 100% mortality to *F. cobboldi* only after 12 h incubation with 500 to 2000 µg/ml of *Terminalia catappa* crude extract. Studies on closely related trematode species also showed similar results when treated with crude plant extracts. Treatment of 750 to 1000 µg/ml crude extract of *Artocarpus lakoocha* showed complete immobilization and death of another trematode *Fasciola gigantica* in 20 to 24 h time (Saowakon et al., 2009). According to Tandon et al. (1997), treatment of *Paramphistomum* species, with 500 µg/ml of *Flemingia vestita* extract caused its death after 12 h. The broad-spectrum anthelmintic drug ABZ, were used as a positive control (Halton, 2004; Hossain et al., 2012; Anuracpreeda et al., 2016) for the anthelmintic studies against trematode parasites at a concentration of

the way for the search and discovery of new treamatocidal drugs (Keiser and Utzinger, 2005) that are safe to the host animals. Here, we study the *in vitro* anthelmintic potentials of *L. toxicaria*, *K. rotunda*, *D. gangeticum* and *T. involucrata* extracts against the adult fluke, *F. cobboldi*. The results clearly showed the capability of *K. rotunda* ethyl acetate extract (KRE) to 1 mg/ml. The results are consistent with the earlier observations (Hossain et al., 2012; Anuracpreeda et al., 2016) where 1 mg/ml ABZ-treated flukes required more time to show reduced motility.

The microscopy and histology studies showed that the tegument is the most affected region when treated with ethyl acetate and ethanolic extracts of all plant extracts. Same time water extracts showed no prominent tegumental alterations to *F. cobboldi*. The tegumental region of parasites is important in that they help evade many of the host defenses effectively. It plays a chief role in protecting the flukes from host enzymes and immune responses. Additionally, it supports the internal organs, helps maintain the absorption and exchange of nutritive and waste products, maintains osmoregulation and perceives sensory stimuli (Sobhon and Upatham, 1990; Meaney et al., 2002, 2003, 2004; Anuracpreeda et al., 2015, 2016). The present study showed important



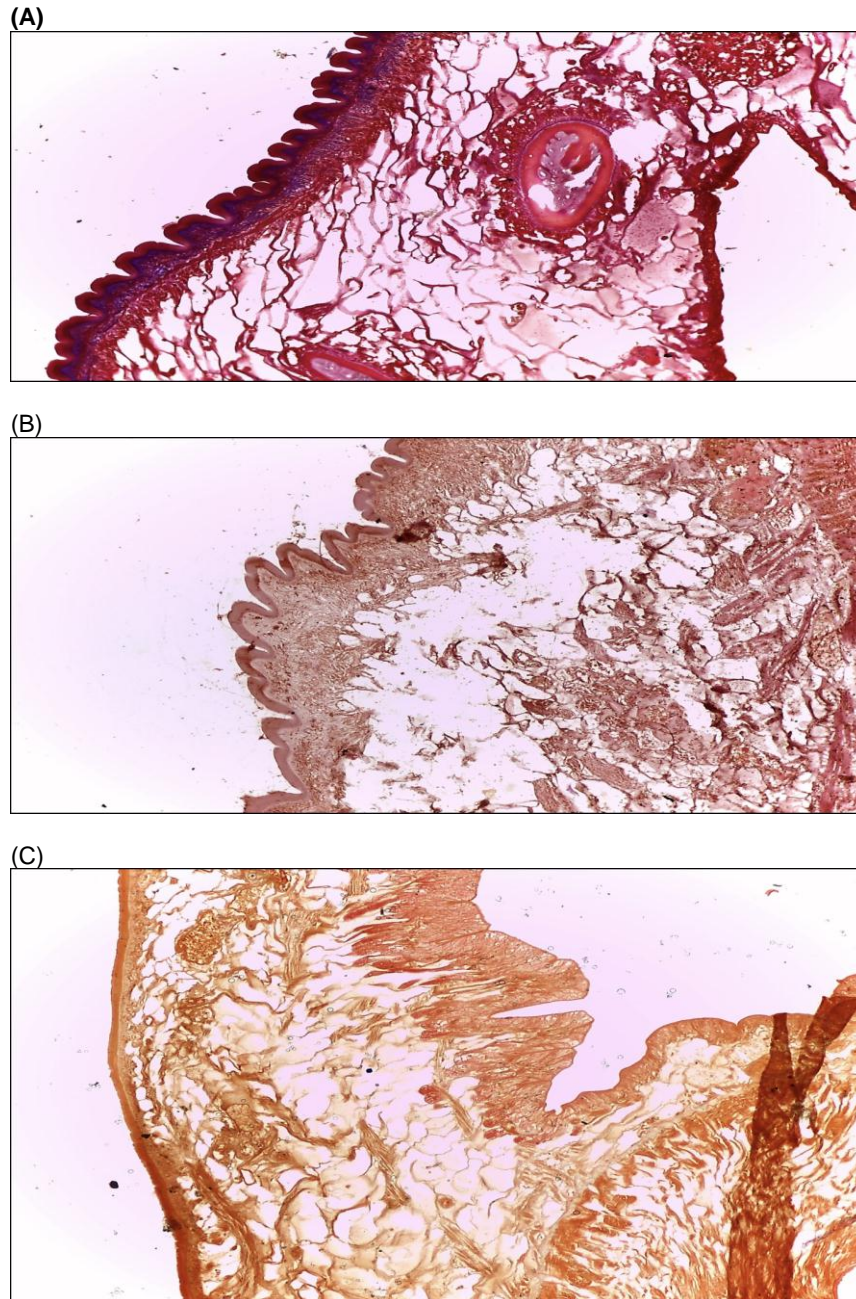
**Figure 6.** H and E stained biopsy of the adult *F. cobboldi* treated with vehicle control, ABZ and plant extract (100× magnification). (A) Vehicle control treatment did not affect the normal tissue architecture. It showed intact surface syncytium (Ss) and underlying muscle tissue (Mu). (B) ABZ (1 mg/ml) treatment showed mild degeneration of surface syncytium (Ssd) whereas the underlying muscle appears normal. (C) Following 1h of KRE treatment, appearance of severe degeneration to surface syncytium (Ssd) and teguments.

alterations to the tegumental regions include severe degeneration and sloughing followed by extensive erosion when treated with ethyl acetate and ethanol extracts.

The mechanistic aspect by which the phytochemical

constituents exert this action is not fully clear. Also, the multicomponent extracts may have multiple targets especially since these small molecules can easily be absorbed in the damaged tegument system of these invertebrates (Hrckova and Velebny, 2013). The





**Figure 7.** Masson's trichrome staining to observe changes in the connective tissues (100x magnification). (A) Vehicle control treatment did not affect the normal tissue architecture and the basement membrane collagen layer is clearly visible. (B) Slightly denatured muscle architecture in the ABZ treated animals and the disappearance of collagen. (C) Severe damage to the outer syncytium and loss of muscle attachment. Complete absence of any fibrous collagen.

tegumental desquamation and alterations to the underlying musculature to the *F. cobboldi* in the present extract of *B. malabaricum* (Hossain et al., 2012), *Gastrothylax crumenifer* treated with *Dicranopteris linearis* extracts (Rajesh et al., 2016) and *F. cobboldi* treated with *T. catappa* crude extracts

study showed similarity to that investigated in adult *Paramphistomum explanatum* treated with methanol (Anuracpreeda et al., 2016).

The treated trematodes in the present case exhibited irregular swollen regions with deep grooves and blebs which according to Stitt and Fairweather (1993) could be

considered as an adaptive response of the parasite to withstand a stressful condition, including the flukes attempt for repairing the damaged areas. Skuce et al. (1987) reported that the swellings on the surface could be considered as the after-effects of disruptions to the ion pumps at the apical plasma membrane that results in osmotic imbalance. Drastic degradation of the tegumental surface by plant extracts was visible in our microscopy studies. Degeneration of the surface layer could help the drugs, penetrate deeper into the muscle cells, and cause motility reduction and death to the flukes (Rajesh et al., 2016). Regional specific differences were also evident when treated with extracts. The ventral surface is the most affected compared to the dorsal surface. Alongside, ingestion of the extract by the flukes might have resulted in the alterations to the swollen appearance and formation of irregular blebs on sucker regions. The biopsy studies revealed a smooth (less corrugated) outer body cuticle in the treated animals. Further, there was collagen loss in tissues of treated trematodes. To produce structurally ordered cuticle, interactions must take place between collagens. Triple helices must be formed by interaction between collagen monomers for developing the final polymerized macromolecular structure (Johnstone, 1994). The condensed tannins have high affinity for proteins and bind with them to alter its physical and chemical properties (Hoste et al., 2006). It may thus be one of the reasons for altered cuticle structure seen in the sections of amphistomes treated with ethyl acetate extracts of the plants. The loss of this important protein interaction can lead to the cuticular damage and hence, mortality of amphistomes.

## Conclusion

The immediate onset of mortality in the KRE treatment is indicative of the multitargeted effect whereby some components change the tegumental structure facilitating easy entry of other molecules to the interior tissues to cause its mortality. The extract is therefore recommended for toxicity studies using mice models and the non-toxic concentration can be further promoted for veterinary use to treat paramphistomosis.

## CONFLICT OF INTERESTS

The authors have not declared any conflict of interests.

## ACKNOWLEDGEMENT

This study was partially supported by the Kerala State Council for Science, Technology, and Environment (KSCSTE) Government of Kerala, Letter No. 1185/2015/KSCSTE.

## REFERENCES

- Adesegun SA, Ayoola GA, Coker HA, Adepoju-Bello AA, Obaweya K, Ezennia EC, Atangbayila TO (2008). Phytochemical Screening and Antioxidant Activities of Some Selected Medicinal Plants Used for Malaria Therapy in Southwestern Nigeria. In *Tropical Journal of Pharmaceutical Research* 7(3):1019-1024. <https://doi.org/10.4314/tjpr.v7i3.14686>
- Aggarwal R, Kaur K, Suri M, Bagai U (2016). Anthelmintic potential of *Calotropis procera*, *Azadirachta indica* and *Punica granatum* against *Gastrothylax indicus*. *Journal of Parasitic Diseases* 40(4):1230–1238. <https://doi.org/10.1007/s12639-015-0658-0>
- Anuracpreeda P, Chankaew K, Puttarak P, Koedrih P, Chawengkirtikul R, Panyarachun B, Ngamniyom A, Chanchai S, Sobhon P (2016). The anthelmintic effects of the ethanol extract of *Terminalia catappa* L. leaves against the ruminant gut parasite, *Fischoederius cobboldi*. *Parasitology* 143(4):421-433.
- Anuracpreeda P, Chawengkirtikul R, Tinikul Y, Poljaroen J, Chotwiwatthanakun C, Sobhon P (2013). Diagnosis of *Fasciola gigantica* infection using a monoclonal antibody-based sandwich ELISA for detection of circulating cathepsin B3 protease. *Acta Tropica* 127(1):38-45.
- Anuracpreeda P, Panyarachun B, Ngamniyom A, Tinikul Y, Chotwiwatthanakun C, Poljaroen J, Sobhon P (2012). *Fischoederius cobboldi*: A scanning electron microscopy investigation of surface morphology of adult rumen fluke. *Experimental Parasitology* 130(4):400–407.
- Anuracpreeda P, Phutong S, Ngamniyom A, Panyarachun B, Sobhon P (2015). Surface topography and ultrastructural architecture of the tegument of adult *Carmyerius spatiosus* Brandes, 1898. *Acta Tropica* 143(1):18-28.
- Anuracpreeda P, Srirakam T, Pandonlan S, Changklungmoa N, Chotwiwatthanakun C, Tinikul Y, Poljaroen J, Meemon K, Sobhon P (2014). Production and characterization of a monoclonal antibody against recombinant cathepsin L1 of *Fasciola gigantica*. *Acta Tropica* 136(1):1-9.
- Apinhasmit W, Sobhon P, Saitongdee P, Menayotin S, Upatham ES (1994). *Opisthorchis viverrini*: Ultrastructure of the tegument of the first-week juveniles and adult flukes. In *International Journal for Parasitology* 24(5):613-621. [https://doi.org/10.1016/0020-7519\(94\)90113-9](https://doi.org/10.1016/0020-7519(94)90113-9)
- Athanasiadou S, Githiori J, Kyriazakis I (2007). Medicinal plants for helminth parasite control: facts and fiction. *Animal: An International Journal of Animal Bioscience* 1(9):1392-1400.
- Atun S, Arianingrum R, Sulistyowati E, Aznam N (2013). Isolation and antimutagenic activity of some flavanone compounds from *Kaempferia rotunda*. In *International Journal of Chemical and Analytical Science* 4(1):3-8. <https://doi.org/10.1016/j.ijcas.2013.03.004>
- Choubisa SL, Jaroli VJ (2013). Gastrointestinal parasitic infection in diverse species of domestic ruminants inhabiting tribal rural areas of southern Rajasthan, India. *Journal of Parasitic Diseases: Official Organ of the Indian Society for Parasitology* 37(2):271-275.
- Darney GR. (1974). *Chemotaxonomy of Flowering Plants: Four Volumes*. McGill-Queen's Press - MQUP.
- Dorny P, Stolaroff V, Charlier J, Meas S, Sorn S, Chea B, Holl D, Van Aken D, Vercruysse J (2011). Infections with gastrointestinal nematodes, *Fasciola* and *Paramphistomum* in cattle in Cambodia and their association with morbidity parameters. *Veterinary Parasitology* 175(3-4):293-299.
- Evans WC, Evans D, Trease GE (2002). *Trease and Evans Pharmacognosy*. Bailliere Tindall.
- Halton DW (2004). Microscopy and the helminth parasite. In *Micron* 35(5):361-390. <https://doi.org/10.1016/j.micron.2003.12.001>
- Hanna RE, Williamson DS, Mattison RG, Nizami WA (1988). Seasonal reproduction in *Paramphistomum epiclitum* and *Gastrothylax crumenifer*, rumen paramphistomes of the Indian water buffalo, and comparison with the biliary paramphistome *Gigantocotyle explanatum*. *International Journal for Parasitology* 18(4):513-521.
- Heinrich M (2003). Plant Resources of South-East Asia 12 (3): Medicinal and Poisonous Plants 3. *Journal of Ethnopharmacology* 87(1):119. [https://doi.org/10.1016/s0378-8741\(03\)00056-4](https://doi.org/10.1016/s0378-8741(03)00056-4)

- Hossain E, Chandra G, Nandy AP, Mandal SC, Gupta JK (2012). Anthelmintic effect of a methanol extract of *Bombax malabaricum* leaves on *Paramphistomum explanatum*. *Parasitology Research* 110(3):1097-1102.
- Hoste H, Jackson F, Athanasiadou S, Thamsborg SM, Hoskin SO (2006). The effects of tannin-rich plants on parasitic nematodes in ruminants. *Trends in Parasitology* 22(6):253-261.
- Hrcakova G, Velebny S (2013). Pharmacological Potential of Natural Compounds in the Control of Selected Protozoan Diseases. *Pharmacological Potential of Selected Natural Compounds in the Control of Parasitic Diseases*. 1–28. [https://doi.org/10.1007/978-3-7091-1325-7\\_1](https://doi.org/10.1007/978-3-7091-1325-7_1)
- Johnstone IL (1994). The cuticle of the nematode *Caenorhabditis elegans*: a complex collagen structure. *BioEssays: News and Reviews in Molecular, Cellular and Developmental Biology* 16(3):171-178.
- Kabir SR, Hossen A, Zubair A, Alom J, Islam F, Hossain A, Kimura Y (2011). A new lectin from the tuberous rhizome of *Kaempferia rotunda*: isolation, characterization, antibacterial and antiproliferative activities. *Protein and Peptide Letters* 18(11):1140-1149.
- Kar A, Choudhary BK, Bandyopadhyay NG (2003). Comparative evaluation of hypoglycaemic activity of some Indian medicinal plants in alloxan diabetic rats. *Journal of Ethnopharmacology* 84(1):105-108.
- Kaur S, Singla LD, Hassan SS, Juyal PD (2008). Evaluation of Dot-ELISA for immunodiagnosis of *Paramphistomum epiclitum* in ruminants. *Journal of Parasitic Diseases* 32:118-122.
- Keiser J, Utzinger J (2005). Emerging foodborne trematodiasis. *Emerging Infectious Diseases* 11(10):1507-1514.
- Kirtikar KR, Basu BD (1987). *Indian Medicinal Plants* (Vol. 1–4). Lalit Mohan Basu, Allahabad: Jayyed Press.
- Kiuchi F, Miyashita N, Tsuda Y, Kondo K, Yoshimura H (1987). Studies on crude drugs effective on visceral larva migrans. I. Identification of larvicidal principles in betel nuts. *Chemical and Pharmaceutical Bulletin* 35(7):2880-2886.
- Meaney M, Fairweather I, Brennan GP, Forbes AB (2004). Transmission electron microscope study of the ultrastructural changes induced in the tegument and gut of *Fasciola hepatica* following in vivo drug treatment with clorsulon. *Parasitology Research* 92(3):232-241.
- Meaney M, Fairweather I, Brennan GP, McDowell LSL, Forbes AB (2003). *Fasciola hepatica* : effects of the fasciolicide clorsulon in vitro and in vivo on the tegumental surface, and a comparison of the effects on young- and old-mature flukes. *Parasitology Research* 91(3): 238–250. <https://doi.org/10.1007/s00436-003-0863-0>
- Meaney M, Fairweather I, Brennan GP, Ramasamy P, Subramanian PB (2002). *Fasciola gigantica*: tegumental surface alterations following treatment in vitro with the sulphoxide metabolite of triclabendazole. *Parasitology Research* 88(4):315-325.
- Murthy GSS, Rao PV (2014). Prevalence of gastro intestinal parasites in ruminants and poultry in Telangana region of Andhra Pradesh. *Journal of Parasitic Diseases: Official Organ of the Indian Society for Parasitology* 38(2):190-192.
- Paech K (1962). *Modern Methods of Plant Analysis, Vol. 5*.
- Priya MJ, Nath LK, Bhuyan N, Mariappan G (2008). Evaluation of Antioxidant Potential of *Kaempferia rotunda* Linn. *Indian Journal of Pharmaceutical Sciences* 70(3):362-364.
- Rajesh KD, Subramani V, Annamalai P, Nakulan RV, Narayanaperumal J, Solomon J (2016). In vitro study of trematocidal action of *Dicranopteris linearis* (Burm.f.) Underw. extracts against *Gastrothylax crumenifer*. *Biomedicine and Pharmacotherapy = Biomedecine and Pharmacotherapie* 84:2042-2053.
- Sanguankiat S, Sato MO, Sato M, Maipanich W, Yoonuan T, Pongvongsa T, Waikagul J (2016). First record of paramphistomes *Fischoederius cobboldi* and *Paramphistomum epiclitum* detected in bovine rumen from a local market of savannakhet province, Lao PDR. *The Korean Journal of Parasitology* 54(4):543.
- Saowakon N, Tansatit T, Wanichanon C, Chanakul W, Reutrakul V, Sobhon P (2009). *Fasciola gigantica*: anthelmintic effect of the aqueous extract of *Artocarpus lakoocha*. *Experimental Parasitology* 122(4):289-298.
- Selvakumari PAS. (2014). Pharmacognostical Standardisation of *Lagenandra toxicaria* DALZ. In *Malaysian Journal of Science* 33(2):163-175. <https://doi.org/10.22452/mjs.vol33no2.5>
- Sereena K, Prakash Kumar U, Ab RS (2011). Histochemical and Phytochemical Markers for the Authentication of Ayurvedic Raw drug hallakam (*Kaempferia rotunda*) and its Marketed Adulterant. *International Journal of Pharmaceutical Sciences And Research* 2(11):2952-2958.
- Skuce PJ, Anderson HR, Fairweather I. (1987). The interaction between the deacetylated (amine) metabolite of diamphenethide (DAMD) and cytochemically demonstrable Na<sup>+</sup>/K<sup>+</sup>-ATPase activity in the tegument of *Fasciola hepatica*. *Parasitology Research* 74:161-167.
- Sobhon P, Upatham ES. (1990). Snail Hosts, Life-cycle, and Tegumental Structure of Oriental Schistosomes.
- Stitt AW, Fairweather I (1993). *Fasciola hepatica*: the effect of the microtubule inhibitors colchicine and tubulozole-C on the ultrastructure of the adult fluke. *Parasitology* 107(Pt 3):297-309.
- Swarnakar G, Kumawat A. (2014) In vitro anthelmintic effect of *Citrullus colocynthis* on tegument of amphistomes *Orthocoelium scolioceolium* (Trematoda: Digenea). *International Journal of Current Microbiology and Applied Sciences* 3:571-582.
- Tandon V, Pal P, Roy B, Rao HSP, Reddy KS (1997). In vitro anthelmintic activity of root-tuber extract of *Flemingia vestita*, an indigenous plant in Shillong, India. *Parasitology Research* 83(5):492-498. <https://doi.org/10.1007/s004360050286>
- Tandon V, Roy B, Shylla JA, Ghatani S. (2014). Amphistomes. *Advances in Experimental Medicine and Biology* (pp.365-392). [https://doi.org/10.1007/978-1-4939-0915-5\\_11](https://doi.org/10.1007/978-1-4939-0915-5_11)
- Tariq KA, Chishti MZ, Ahmad F, Shawl AS. (2008). The epidemiology of paramphistomosis of sheep (*Ovis aries* L.) in the north west temperate Himalayan region of India. *Veterinary Research Communications* 32(5):383-391.
- Tehrani A, Javanbakht J, Khani F, Hassan MA, Khadivar F, Dadashi F, Alimohammadi S, Amani A. (2015). Prevalence and pathological study of *Paramphistomum* infection in the small intestine of slaughtered ovine. *Journal of Parasitic Diseases: Official Organ of the Indian Society for Parasitology* 39(1):100-106.
- Varma GG, Mathai BK, Das K, Gowda G, Rammohan S, Einstein JW. (2014). Evaluation of Antiepileptic Activity of Methanolic Leaves Extract of *Tragia involucrata* Linn. in Mice. *International Letters of Natural Sciences* 17:167-179. <https://doi.org/10.18052/www.scipress.com/ilns.17.167>
- Woerdenbag HJ, Windono T, Bos R, Riswan S, Quax WJ. (2004). Composition of the essential oils of *Kaempferia rotunda* L. and *Kaempferia angustifolia* Roscoe rhizomes from Indonesia. *Flavour and Fragrance Journal* 19(2):145-148. <https://doi.org/10.1002/ffj.1284>